

Words on The Occasion of Publication of Study Report on Synthesized 18-lead ECG



HIROAKI SHIMOKAWA,
M.D., Professor

Department of Cardiovascular Medicine,
 Tohoku University Graduate School of
 Medicine



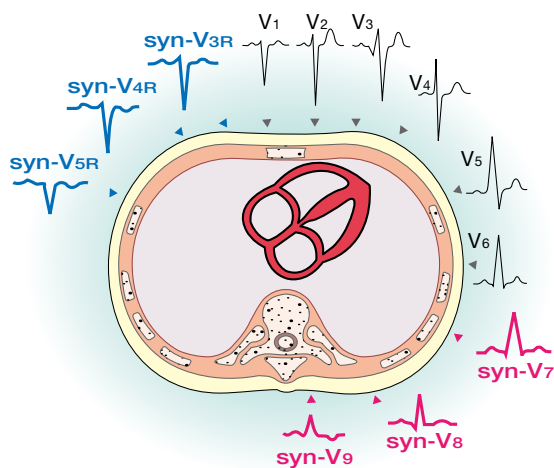
DAMING WEI,
Ph.D., Professor

Director of Biomedical Information
 Technology Lab, The University of Aizu

The mortality rate from ischemic heart disease in Japan has been reported to be 63.4 and 50.0 per 100,000 in male and female, respectively. According to the MONICA Study, it is estimated that the morbidity rates of myocardial infarction (MI) per year are approximately 38 (20-50) and 12 (10-30) in male and female, respectively (Guidelines for the Management of Patients with ST-elevation Myocardial Infarction; Japanese Circulation Society). Needless to say, diagnosis of ischemic heart disease and acute MI is very important.

Moreover, these guidelines also refer to the importance of electrocardiograph (ECG) in the management of these diseases, especially in recording V4R to evaluate possible right ventricular MI and leads V7, V8 and V9 to evaluate possible posterior infarction. However, these leads are rarely measured in routine diagnostic procedure. The synthesized 18-lead ECG to be introduced shows the measurement of right-sided precordial leads V3R, V4R and V5R and posterior leads V7, V8 and V9 calculated from measurement of standard 12-lead ECG.

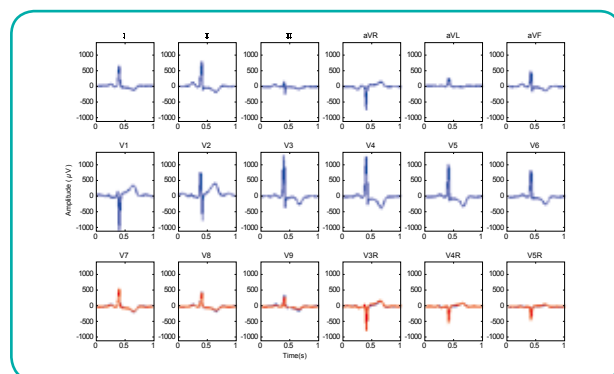
I believe that combining these synthesized extended leads with standard 12-lead ECG will enable easier detection of right ventricular MI and posterior infarction than only standard 12-lead ECG.



Synthesized ECG on Extended Posterior and Right Precordial Leads – Principle and Clinical Applications

While 12-lead electrocardiogram (ECG) is a clinical standard, it is not sensitive enough to detect some diseases like acute myocardial infarction (AMI) taking place on posterior or right ventricular walls. In such circumstances, ECGs recorded from extended leads on V7, V8 and V9, or V3R, V4R, V5R and V6R are usually desired. However, it is not only a very complicated process to attach electrodes on the back of the body, but also standard 12-lead electrocardiograph is not capable of recording ECG on extended leads during routine clinical recording.

We present a work that synthesizes ECGs on the extended leads of V7, V8 and V9, or V3R, V4R and V5R using ECG signals from standard 12-lead ECG recording. The theoretical principle of synthesis is based on information redundancy, so that the extended leads can be expressed by a linear combination of the recorded leads for the 12-lead ECG. We evaluated our method using several hundred of clinical ECG data recorded from Tohoku University Hospital, Nihon University Hospital, and other medical centers. Satisfied accuracy from clinical application standard was obtained, which included correlations of waveform, and potentials differences between the synthesized and measured ECGs. The figure shows an example where the detected and synthesized ECGs of extended leads are overlapped. This study provides a computer-aided means for diagnosis of posterior and right ventricular AMI without having to record posterior and right precordial ECGs.





**TAKAO
KATO,**
M.D., Professor

Department of Internal Medicine,
Nippon Medical School

Synthesized 18-lead ECG, which I presented as research findings at a symposium of the International Society of Holter and Noninvasive Electrocardiology in 2009, is to be introduced as a viewer on the PC, and now I have a high expectation for its future applications at actual site.

This synthesized 18-lead ECG method is to derive measurements of right-sided leads V3R, V4R and V5R and posterior leads V7, V8 and V9 using ECG signals from standard 12-lead ECG recording. Here I'd like to introduce one of the cases reported by clinic of Nippon Medical School, where I found this method to be useful in routine diagnosis.

Figure 1 is an ECG of a patient (60 years old, male) with chest pain obtained at the initial visit on March 8, 2008.

As shown in Fig.1, ST elevation appears in leads II, III and aVF of standard 12-lead ECG, which indicates the patient has inferior infarction while diagnosis of right ventricular MI is uncertain since ST change is less recognized in leads aVR, V1 and V2.

In contrast, derived right-sided precordial leads (V3R, V4R, and V5R; Synthesized) clearly shows ST elevation, which strongly indicates the patient has right ventricular MI.

Actual ECG waveform (V3R, V4R, and V5R; Actual) recorded by actually placing electrodes also shows ST elevation, which indicate good consistency of Synthesized and Actual ECG waveform. Therefore, it can be said that these derived right-sided precordial leads reflect the status of right ventricular MI well although it would be difficult to diagnose MI extended to the right ventricular by only standard 12-lead ECG.

When MI is suspected in clinical settings, it is obviously critical to determine the infarcted area in an early stage and provide appropriate treatment promptly. This easy-to-use synthesized 18-lead ECG method is clinically useful for evaluating the status of right ventricular and posterior of the heart, which is difficult for standard 12-lead ECG.

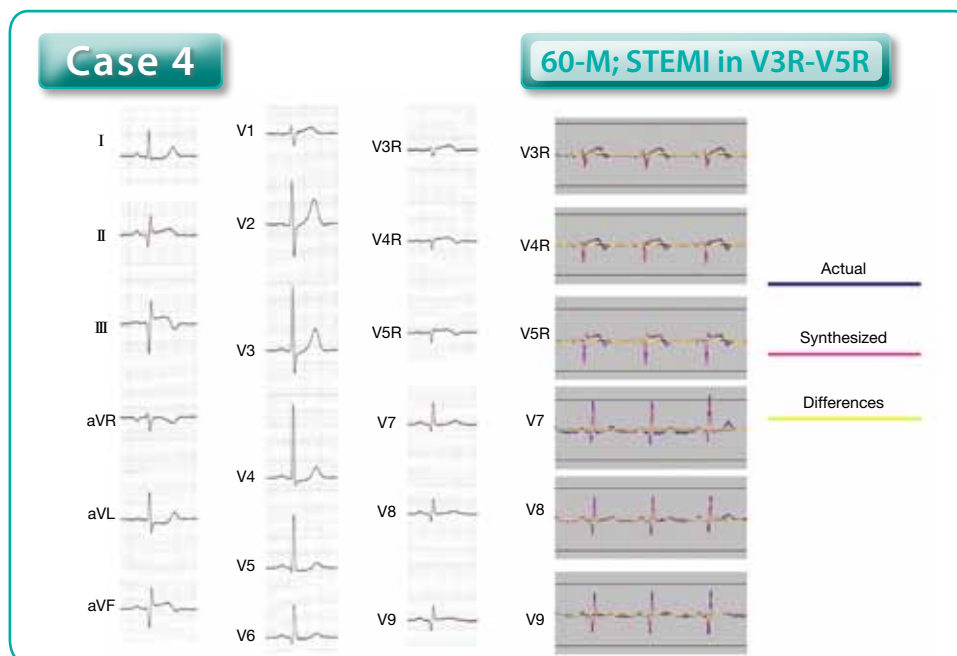


Fig. 1